

BRIGHAM HEALTH



BRIGHAM AND  
WOMEN'S HOSPITAL

# Life-Threatening Cardiac Arrhythmias in the ICU

**Thomas M. Tadros, MD, MPH**

*Cardiac Electrophysiologist*

*Brigham and Women's Hospital*

*Instructor*

*Harvard Medical School*



HARVARD MEDICAL SCHOOL  
TEACHING HOSPITAL

MAGNET  
RECOGNIZED



AMERICAN NURSES  
CREDENTIALING CENTER

# Disclosures

None

# Overview

- Bradycardias
  - Sinus arrest
  - AV Block
- Tachycardias
  - Ventricular Tachycardia
  - Unspecified Wide Complex Tachycardia
- Cardiac Arrest
  - Shockable rhythms
    - VF
    - Pulseless VT
  - Non-shockable rhythms
    - Asystole
    - Pulseless electrical activity (PEA)



## Critical Care Medicine

### Certification Examination Blueprint

Medical Content Category	% of Exam
Renal, Endocrine, and Metabolic Disorders	15.0%
Cardiovascular Disorders	17.5%
Pulmonary Disease	20.0%
Infectious Disease	12.0%
Gastrointestinal Disorders	5.0%
Neurologic Disorders	9.5%
Hematologic and Oncologic Disorders	5.5%
Surgery, Trauma, and Transplantation	7.0%
Pharmacology and Toxicology	4.5%
Research, Administration, and Ethics	2.0%
Critical Care Ultrasound Scanning	2.0%
	100%

### Arrhythmias

<2%

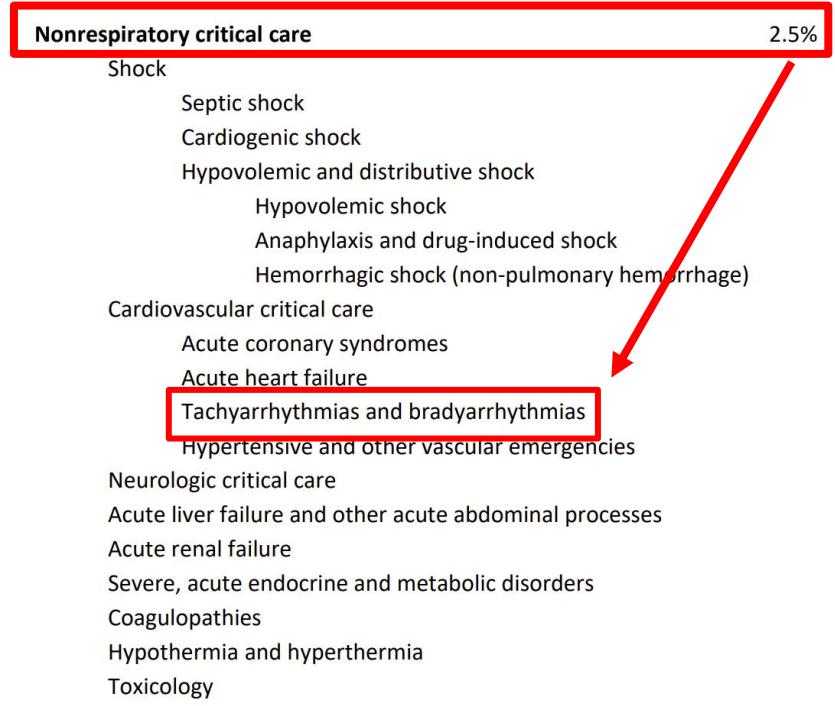
- Supraventricular tachycardia
  - Atrial fibrillation
  - Atrial flutter
  - Multifocal atrial tachycardia
  - Pre-excitation syndromes
  - Paroxysmal supraventricular tachycardia
    - (atrioventricular [AV] nodal reentrant tachycardia)
- Ventricular arrhythmias
  - Nonsustained ventricular tachycardia
  - Monomorphic ventricular tachycardia
  - Polymorphic ventricular tachycardia
  - Ventricular fibrillation
  - Accelerated idioventricular rhythm
  - Long QT syndrome
  - Brugada syndrome
- Bradycardias
  - Sinus bradycardia
  - Sinoatrial exit block
  - Atrioventricular block
- Pacemakers and defibrillators



**Pulmonary Disease**

Certification Examination Blueprint

Medical Content Category	% of Exam
Obstructive Lung Disease	17.5%
<b>Critical Care Medicine</b>	<b>15%</b>
Diffuse Parenchymal Lung Disease (DPLD)	10%
Sleep Medicine, Neuromuscular and Skeletal	10%
Epidemiology	2%
Infections	12%
Neoplasia	9.5%
Pleural Disease	5%
Quality, Safety, and Complications	5%
Transplantation	2%
Vascular Diseases	6%
Respiratory Physiology and Pulmonary Symptoms	4%
Occupational and Environmental Diseases	2%
	100%



# Overview

- **Bradycardias**
  - Sinus arrest
  - AV Block
- Tachycardias
  - Ventricular Tachycardia
  - Unspecified Wide Complex Tachycardia
- Cardiac Arrest
  - Shockable rhythms
    - VF
    - Pulseless VT
  - Non-shockable rhythms
    - Asystole
    - Pulseless electrical activity (PEA)

# Case #1

A 79 year old woman with persistent atrial fibrillation and type 2 diabetes presented to the emergency room with malaise and dyspnea. She was diagnosed with bacterial endocarditis based upon fever, positive blood cultures with Gram positive cocci, and mitral valve vegetation on echocardiogram. Echocardiogram otherwise had no significant abnormality. EKG revealed atrial fibrillation with complete heart block and regular wide complex escape rhythm 38 bpm. Blood pressure was 96/48 mmHg. She was moderately ill-appearing and tachypneic with bibasilar crackles. Antibiotics were initiated, and the patient was started on a dopamine drip, without significant change in her heart rate or dyspnea.

Which of the following is the most appropriate next step in management of the bradycardia?

- A. Insertion of temporary transvenous pacemaker.
- B. Insertion of semipermanent pacemaker the following morning.
- C. Insertion of permanent pacemaker the following morning.
- D. Sedation and transcutaneous pacing.
- E. Administration of intravenous atropine.

# Case #1

A 79 year old woman with persistent atrial fibrillation and type 2 diabetes presented to the emergency room with malaise and dyspnea. She was diagnosed with bacterial endocarditis based upon fever, positive blood cultures with Gram positive cocci, and mitral valve vegetation on echocardiogram. Echocardiogram otherwise had no significant abnormality. EKG revealed atrial fibrillation with complete heart block and regular wide complex escape rhythm 38 bpm. Blood pressure was 96/48 mmHg. She was moderately ill-appearing and tachypneic with bibasilar crackles. Antibiotics were initiated, and the patient was started on a dopamine drip, without significant change in her heart rate or dyspnea.

Which of the following is the most appropriate next step in management of the bradycardia?

- A. Insertion of temporary transvenous pacemaker.
- B. Insertion of semipermanent pacemaker the following morning.
- C. Insertion of permanent pacemaker the following morning.
- D. Sedation and transcutaneous pacing.
- E. Administration of intravenous atropine.

# Case #1

The patient has symptomatic complete heart block in the setting of endocarditis.

**Answer A (insertion of temporary transvenous pacemaker) is the best answer because the patient has symptomatic bradycardia with hypotension and heart failure that has not responded to dopamine.**

Answer B (insertion of semipermanent pacemaker the following morning) is less appropriate because the patient is unstable requiring more urgent intervention.

Answer C (insertion of permanent pacemaker the following morning) is incorrect because the patient has bacteremia that could seed the hardware, so appropriate timing of insertion of a permanent pacing device would depend on blood culture trends.

Answer D (sedation and transcutaneous pacing) is less appropriate because there is adequate time to insert a transvenous pacemaker that would not require sedation. Nonetheless, having transcutaneous pacing pads in position is an important safety precaution while awaiting insertion of the semipermanent pacemaker.

Answer E (administration of intravenous atropine) is incorrect because atropine would not be expected to have an effect on 3<sup>rd</sup> degree heart block.

# Case #2

A 55 year old woman with morbid obesity is post-operative day 0 after laparoscopic cholecystectomy. She is left intubated for airway support due to suspected airway edema, and admitted to the surgical ICU. Throughout the afternoon, she has 3 episodes of abrupt onset sinus bradycardia and transient AV block with asystolic pauses up to 6 seconds triggered by positioning in the bed and by airway suctioning. EKG revealed normal sinus rhythm with normal intervals and no evidence of ischemia. She was otherwise hemodynamically stable.

What is the most appropriate next step?

- A) Insert a temporary transvenous pacemaker
- B) Insert a semi-permanent pacemaker the following morning
- C) Insert a permanent pacemaker the following morning
- D) Watchful waiting
- E) Start dobutamine infusion

# Case #2

A 55 year old woman with morbid obesity is post-operative day 0 after laparoscopic cholecystectomy. She is left intubated for airway support due to suspected airway edema, and admitted to the surgical ICU. Throughout the afternoon, she has 3 episodes of abrupt onset sinus bradycardia and transient AV block with asystolic pauses up to 6 seconds triggered by positioning in the bed and by airway suctioning. EKG revealed normal sinus rhythm with normal intervals and no evidence of ischemia. She was otherwise hemodynamically stable.

What is the most appropriate next step?

- A) Insert a temporary transvenous pacemaker
- B) Insert a semi-permanent pacemaker the following morning
- C) Insert a permanent pacemaker the following morning
- D) Watchful waiting
- E) Start dobutamine infusion

## Case #3

A 76 year old man with longstanding persistent atrial fibrillation treated with digoxin was admitted to the ICU after presenting with 1 week of diarrhea, generalized weakness, and confusion. EKG revealed atrial fibrillation with regular narrow complex rhythm 40 bpm. Blood pressure was stable. Laboratory workup revealed elevated digoxin level, elevated BUN and creatinine, and hyperkalemia 5.6 mEq/L.

In addition to IV fluid resuscitation, which of the following should be part of the initial management strategy?

- A) Temporary transvenous pacemaker
- B) Digoxin-specific antibody
- C) Kayexalate
- D) Intravenous insulin and glucose
- E) Intravenous furosemide

## Case #3

A 76 year old man with longstanding persistent atrial fibrillation treated with digoxin was admitted to the ICU after presenting with 1 week of diarrhea, generalized weakness, and confusion. EKG revealed atrial fibrillation with regular narrow complex rhythm 40 bpm. Blood pressure was stable. Laboratory workup revealed elevated digoxin level, elevated BUN and creatinine, and hyperkalemia 5.6 mEq/L.

In addition to IV fluid resuscitation, which of the following should be part of the initial management strategy?

- A) Temporary transvenous pacemaker
- B) Digoxin-specific antibody**
- C) Kayexalate
- D) Intravenous insulin and glucose
- E) Intravenous furosemide

# Digoxin toxicity

- Can cause various arrhythmias
  - Asystole; Sinus bradycardia; AV block; atrial tachycardia; junctional tachycardia; ventricular tachycardia; VF
- Dig toxicity can occur with normal dig levels (especially in patients with heart failure, ischemia, hypokalemia, hypomagnesemia, hypercalcemia)
- Digoxin inhibits muscle Na-K-ATPase resulting in hyperkalemia
- Hyperkalemia in dig toxicity is a predictor of mortality
- Administer digoxin-specific antibody (Fab fragments)
- After Fab fragments, hyperkalemia is rapidly corrected

# Bradycardia: Etiologies

- Myocardial ischemia or infarction
- Hypoxia
- Electrolyte abnormalities
- Intracranial hypertension
- Vasovagal
- Medications

# Bradycardia: Treatment

- Atropine
  - Effective for sinus bradycardia, AV nodal block, vasovagal
  - Not effective for Mobitz II second degree AV block, complete heart block, or for heart transplant patients
- Dopamine
- Epinephrine
- Isoproterenol
- Transvenous or percutaneous pacing
- If digoxin toxicity: Administer digoxin-specific antibody (Fab) fragments
- If calcium channel blocker toxicity: Administer glucagon

# Bradycardia: Indications for pharmacological or pacing support

- Hypotension
- Acutely altered mental status
- Signs of shock
- Ischemic chest discomfort
- Acute heart failure

# Overview

- Bradycardias
  - Sinus arrest
  - AV Block
- Tachycardias
  - Ventricular Tachycardia
  - Unspecified Wide Complex Tachycardia
- Cardiac Arrest
  - Shockable rhythms
    - VF
    - Pulseless VT
  - Non-shockable rhythms
    - Asystole
    - Pulseless electrical activity (PEA)

# Case #4

A 72 year old woman with ischemic cardiomyopathy, LVEF 30%, ventricular tachycardia treated with ablation 3 years ago plus continued amiodarone, presented to the ER with near syncope and 3 ICD shocks earlier in the day. Physical exam was unremarkable. EKG revealed normal sinus rhythm with normal intervals and no ischemic changes. Labs revealed normal electrolytes and cardiac enzymes. In the ER the patient had 2 additional runs of monomorphic ventricular tachycardia 180 bpm, terminated with anti-tachycardia pacing (ATP) on 1 occasion, and ICD shock on the second occasion. Amiodarone bolus was administered, and she was admitted to the ICU for further management. She continued to have recurrent episodes of monomorphic VT resulting in ATP and ICD shocks.

What is the most appropriate next step in management of her VT?

- A) Adjust the settings on the ICD to avoid ICD shocks
- B) Intubate and sedate with propofol
- C) Urgent coronary angiogram
- D) Procainamide infusion
- E) Urgent anesthesia consult for stellate ganglion block

# Case #4

A 72 year old woman with ischemic cardiomyopathy, LVEF 30%, ventricular tachycardia treated with ablation 3 years ago plus continued amiodarone, presented to the ER with near syncope and 3 ICD shocks earlier in the day. Physical exam was unremarkable. EKG revealed normal sinus rhythm with normal intervals and no ischemic changes. Labs revealed normal electrolytes and cardiac enzymes. In the ER the patient had 2 additional runs of monomorphic ventricular tachycardia 180 bpm, terminated with anti-tachycardia pacing (ATP) on 1 occasion, and ICD shock on the second occasion. Amiodarone bolus was administered, and she was admitted to the ICU for further management. She continued to have recurrent episodes of monomorphic VT resulting in ATP and ICD shocks.

What is the most appropriate next step in management of her VT?

- A) Adjust the settings on the ICD to avoid ICD shocks
- B) Intubate and sedate with propofol
- C) Urgent coronary angiogram
- D) Procainamide infusion**
- E) Urgent anesthesia consult for stellate ganglion block

# Case #4

Answer A (adjust the settings on the ICD to avoid ICD shocks) is incorrect because the ICD shocks have been successful at temporarily restoring sinus rhythm.

Answer B (intubate and sedate with propofol) is incorrect because an alternative antiarrhythmic medication should be attempted first. Intubation/sedation is a reasonable late step for drug-refractory VT storm. It can provide relief of the traumatic experience of recurrent ICD shocks, and possible suppression of VT as has been documented in clinical case reports (possibly by sympathetic blockade, although the mechanism is incompletely understood).

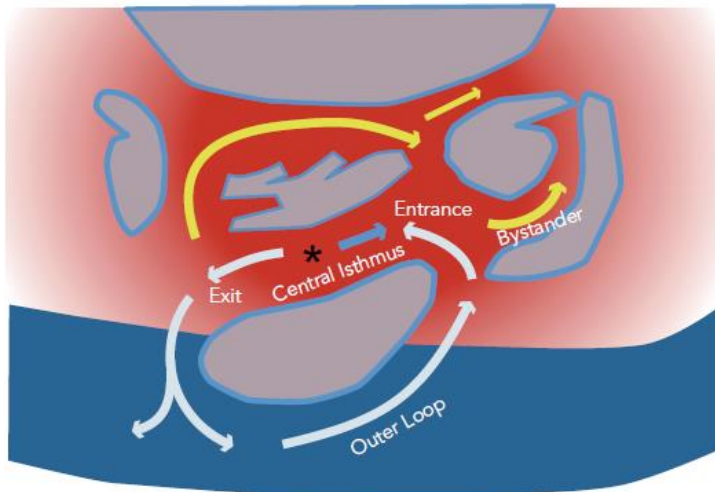
Answer C (urgent coronary angiogram) is incorrect because the patient has no other signs or symptoms of acute coronary syndrome, and monomorphic VT is more likely related to scar from old myocardial infarction and not acute ischemia.

**Correct answer: D (Procainamide infusion). The patient has VT storm (greater than 3 episodes of VT that are sustained or treated with ICD therapies within 24 hours), and she continues to have VT with ICD shocks despite amiodarone. It is reasonable to try to stabilize the VT with another IV antiarrhythmic medication.**

Answer E (urgent anesthesia consult for stellate ganglion block) is incorrect because procainamide could provide quicker relief. Nonetheless, stellate ganglion block would be a reasonable consideration for drug-refractory VT.

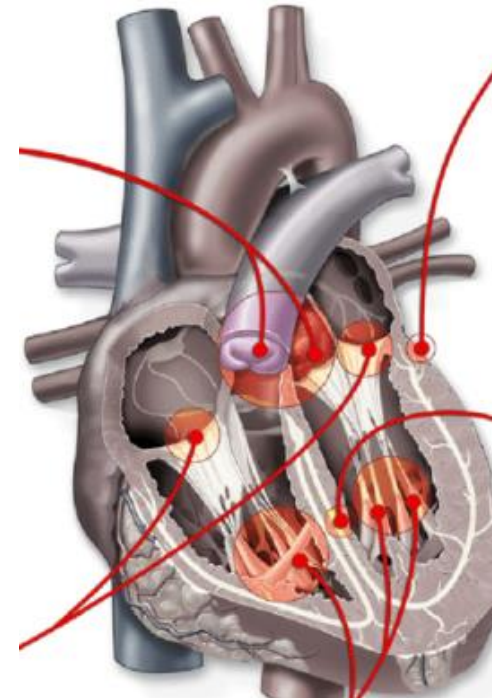
# Monomorphic VT

Reentry



Nof. *Arrhythm Electrophysiol Rev.* 2013  
Stevenson. *Trans Am Clin Climatol Assoc.* 2009;120:403

Automatic/Triggered



Calkins. *Eur Heart J.* 2015

# Polymorphic VT

- Ischemia
- Electrolyte abnormalities
- Heritable channelopathy/cardiomyopathy
  - Long QT syndrome
  - Catecholaminergic polymorphic VT
  - Brugada syndrome
  - Arrhythmogenic cardiomyopathy
- QT prolongation secondary to medications

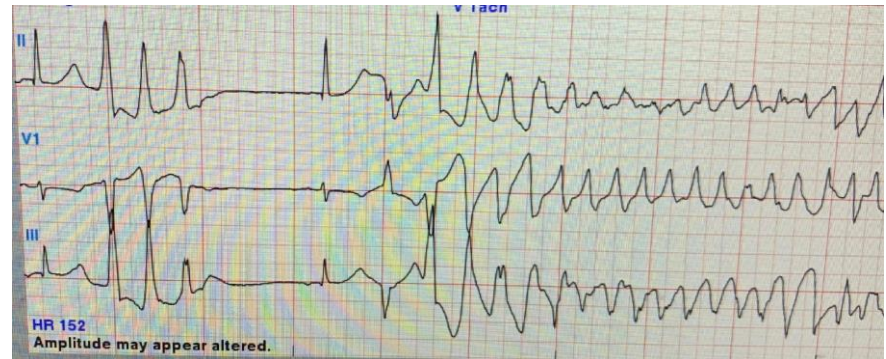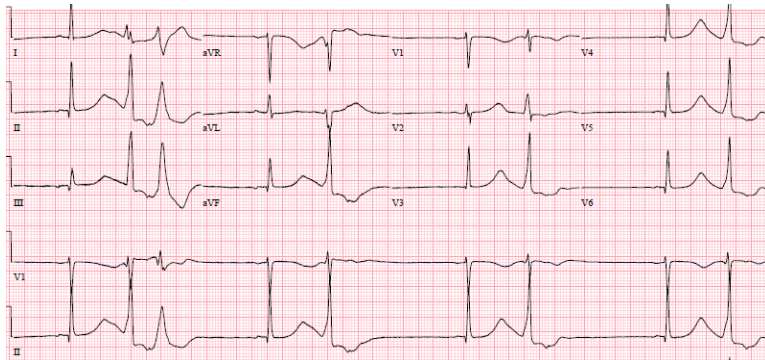
# Hemodynamically Stable VT

## What To do . . .

- Amiodarone
- Sotalol
- Lidocaine
  - Neurotoxicity: tremor; hypoactive delirium; dysarthria; seizures.
  - Monitor lidocaine levels.
- Procainamide
  - Toxicity: PR/QRS/QT prolongation; negative inotropy.
  - Hepatic metabolism to N-acetyl procainamide (NAPA).
  - NAPA active metabolite that is >80% renally cleared/not dialyzable.
  - Monitor procainamide and NAPA concentrations.

# Case #5

- 32 year old female with uterine rhabdomyosarcoma, ESRD on hemodialysis, anxiety treated with citalopram and quetiapine.
- She presented with fever and cough, found to have COVID-19 infection, with oxygen desaturation and elevated inflammatory markers.
- She was treated with remdesivir and prednisone.
- On hospital day #4, she developed sinus bradycardia and ventricular arrhythmia . . .

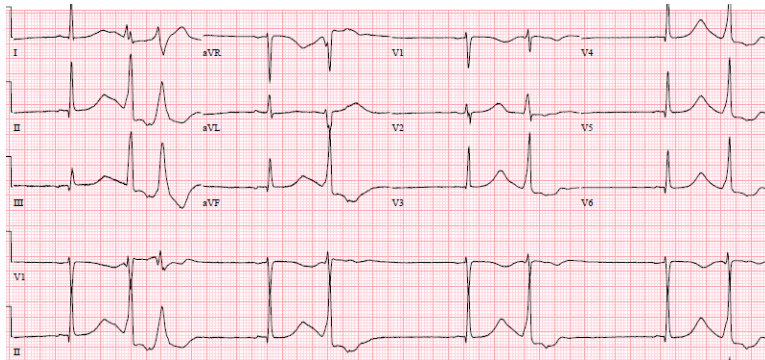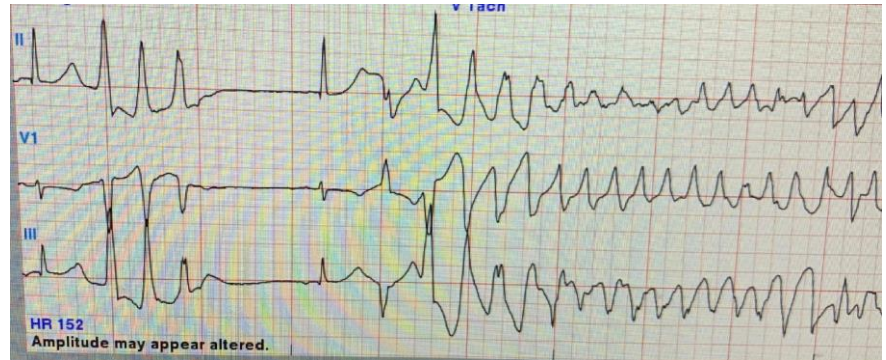


After terminating the ventricular arrhythmia with electrical cardioversion, what is the best next step in management?

- A) Insert a temporary transvenous pacemaker
- B) Apply transcutaneous pacemaker
- C) Administer intravenous amiodarone
- D) Administer magnesium and isoproterenol
- E) Administer intravenous metoprolol

# Case #5

- 32 year old female with uterine rhabdomyosarcoma, ESRD on hemodialysis, anxiety treated with citalopram and quetiapine.
- She presented with fever and cough, found to have COVID-19 infection, with oxygen desaturation and elevated inflammatory markers.
- She was treated with remdesivir and prednisone.
- On hospital day #4, she developed sinus bradycardia and ventricular arrhythmia . . .



After terminating the ventricular arrhythmia with electrical cardioversion, what is the best next step in management?

- A) Insert a temporary transvenous pacemaker
- B) Apply transcutaneous pacemaker
- C) Administer intravenous amiodarone
- D) Administer magnesium and isoproterenol**
- E) Administer intravenous metoprolol

# Case #5

- Diagnosis is Torsades de Pointes
- Polymorphic VT with underlying QT prolongation
- Etiology was polypharmacy
  - QT prolongation secondary to citalopram, quetiapine
  - Bradycardia secondary to remdesivir
- Treat with magnesium sulfate and isoproterenol
- Citalopram, quetiapine, and remdesivir were discontinued.
- Sinus rate improved and QTc normalized

# Torsades de Pointes

- Magnesium Sulfate
  - First line therapy, even if serum Mg concentration is normal
  - Stabilizes excitable membranes
  - Prevents long QT-related ventricular ectopic beats
- Isoproterenol drip
  - For TdP triggered by pauses or bradycardia
  - Titrate to heart rate 100 bpm
  - Beta-1 and beta-2 agonist. Chronotrope. Inotrope. Peripheral vasodilator.
  - Ensure no evidence of ischemia before administering
- Transvenous pacemaker
  - Overdrive pacing of the RA or RV at 100 bpm
  - If no response to Mg or isoproterenol

# Wide Complex Tachycardia Differential Diagnosis

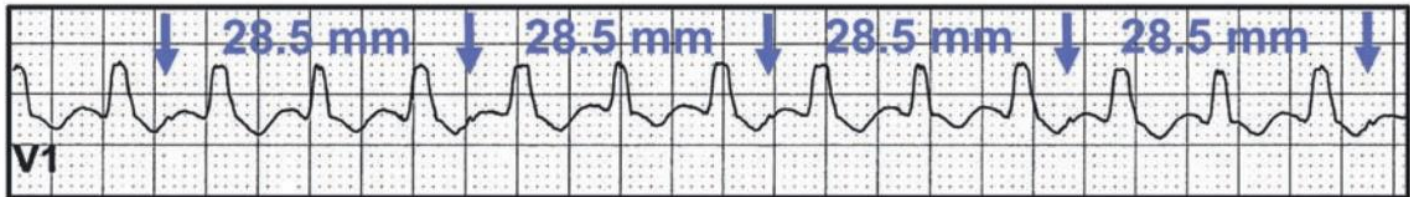
- Ventricular Tachycardia
- SVT with aberrancy
- SVT with preexcitation (WPW syndrome)

# Wide Complex Tachycardia

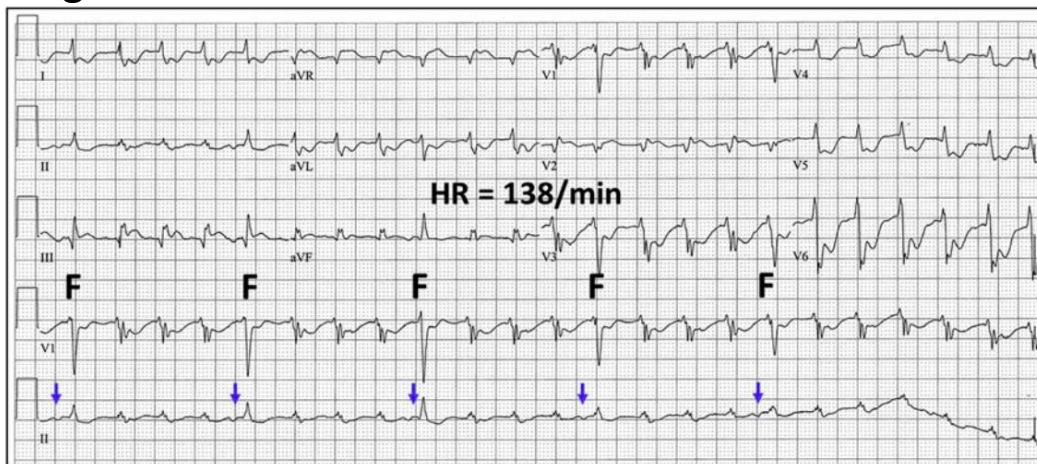
- VT is approximately 4 times more common than SVT with aberrancy or preexcitation
- VT much more common than SVT if history of MI, CHF, or valvular heart disease
- Hemodynamic stability does not rule out VT
- AV dissociation is diagnostic for VT, but present in <50% of VT

# WCT: Tips for EKG Diagnosis AV dissociation is diagnostic for VT

Dissociated P waves at slower rate than the QRS complexes:

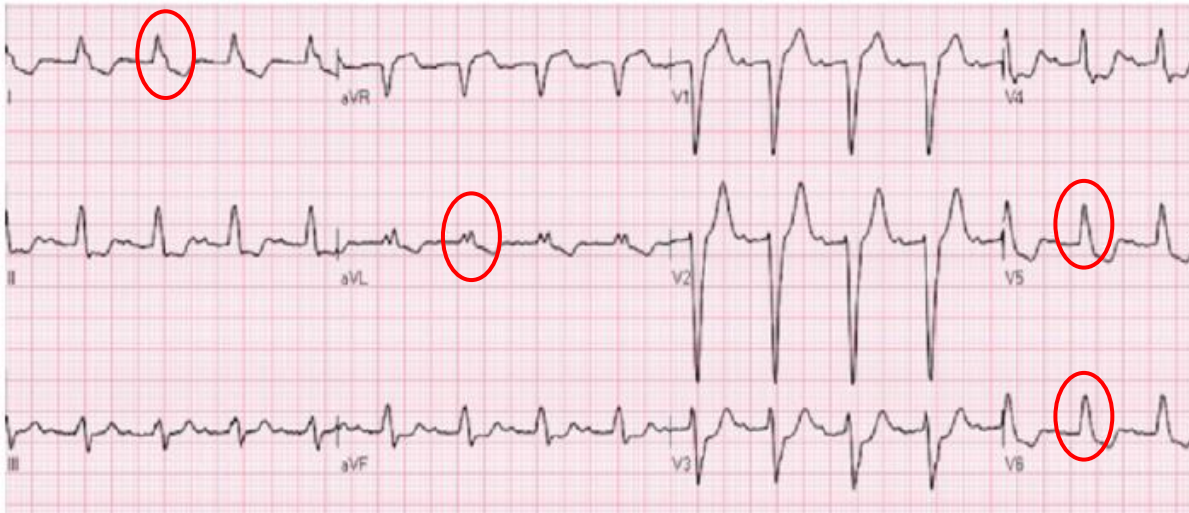


Regular WCT with fusion beats:



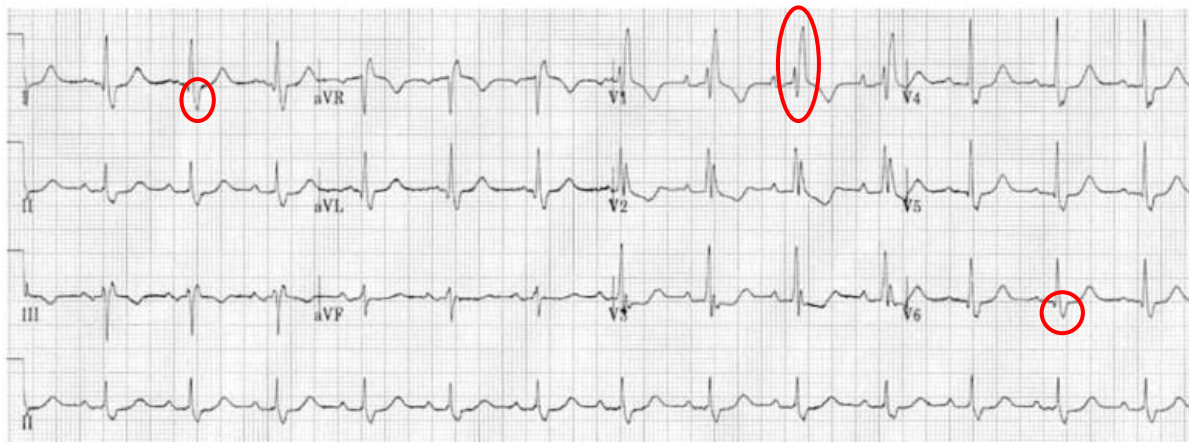
# WCT: tips for EKG diagnosis

## Know appearance of “typical” aberrancy



### LBBB

- Broad or notched R waves I, aVL, V5, V6
- ST and T waves in opposite direction of QRS



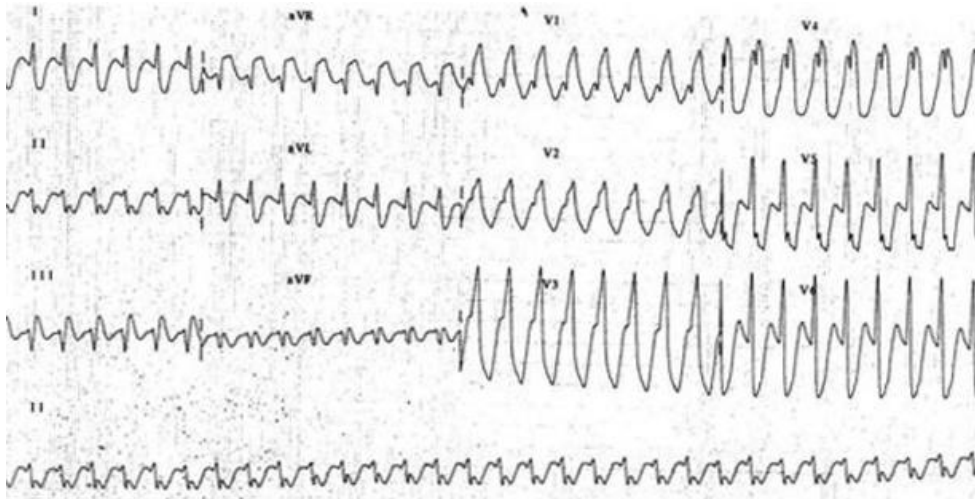
### RBBB

- rsR' in V1
- Broad S wave in V6 and lead I

## Case #6

A 56 year old man with no known heart disease except paroxysmal atrial fibrillation treated with flecainide and metoprolol was admitted to the ICU for community acquired pneumonia with hypoxic respiratory distress. He developed abrupt onset wide complex tachycardia 220 bpm. Blood pressure remained stable. The patient was alert, and noted palpitations but no chest discomfort or increased dyspnea. Prior baseline EKGs revealed no evidence of preexcitation.

Which of the following would NOT be an appropriate first step in management?

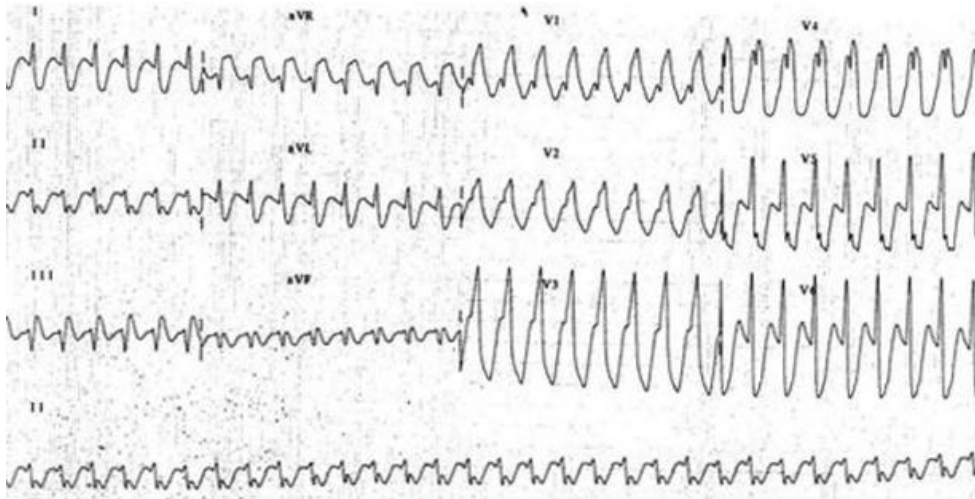


- A) Carotid sinus massage
- B) Adenosine bolus
- C) IV sotalol
- D) IV amiodarone
- E) Electrical cardioversion

## Case #6

A 56 year old man with no known heart disease except paroxysmal atrial fibrillation treated with flecainide and metoprolol was admitted to the ICU for community acquired pneumonia with hypoxic respiratory distress. He developed abrupt onset wide complex tachycardia 220 bpm. Blood pressure remained stable. The patient was alert, and noted palpitations but no chest discomfort or increased dyspnea. Prior baseline EKGs revealed no evidence of preexcitation.

Which of the following would NOT be an appropriate first step in management?



- A) Carotid sinus massage
- B) Adenosine bolus
- C) IV sotalol
- D) IV amiodarone
- E) **Electrical cardioversion**

# Management of Stable Wide Complex Tachycardia

## SPECIFIC ARRHYTHMIA MANAGEMENT

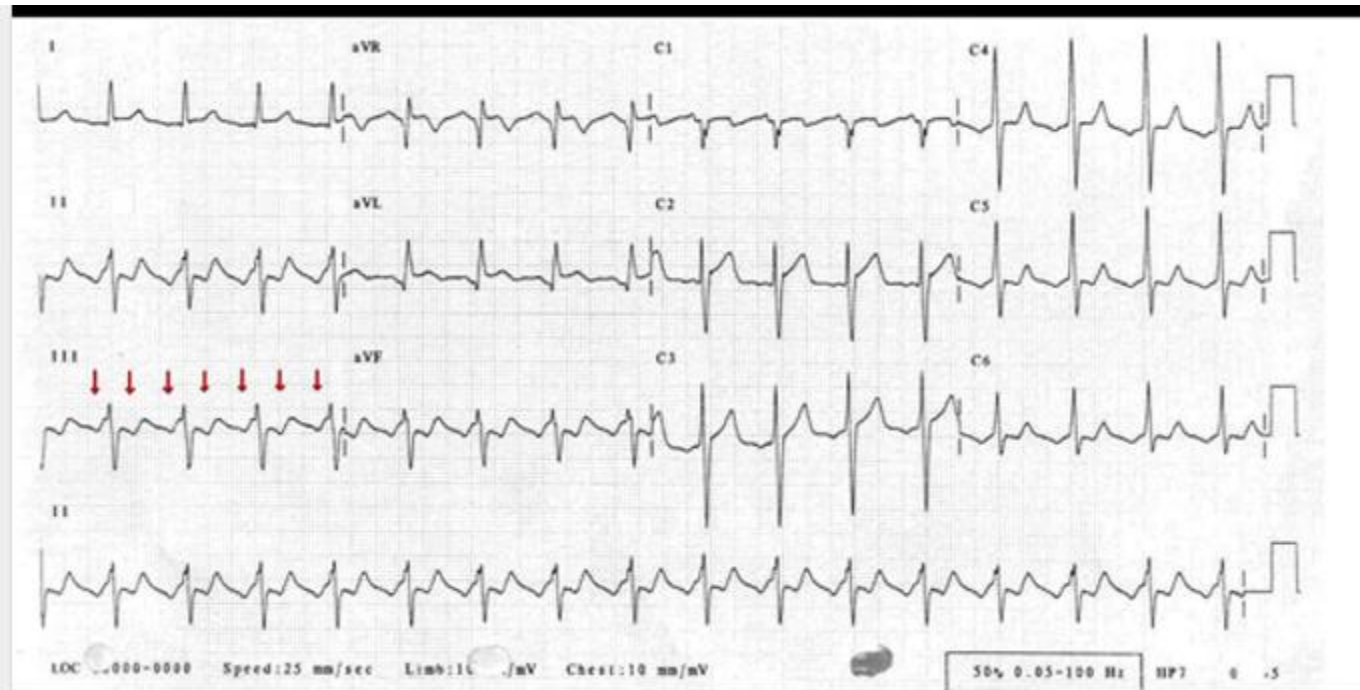
### Wide-Complex Tachycardia

Recommendations for Pharmacological Management of Hemodynamically Stable Wide-Complex Tachycardia		
COR	LOE	Recommendations
2b	B-NR	1. In hemodynamically stable patients, IV adenosine may be considered for treatment and aiding rhythm diagnosis when the cause of the regular, monomorphic rhythm cannot be determined.
2b	B-R	2. Administration of IV amiodarone, procainamide, or sotalol may be considered for the treatment of wide-complex tachycardia.
3: Harm	B-NR	3. Verapamil should not be administered for any wide-complex tachycardia unless known to be of supraventricular origin and not being conducted by an accessory pathway.
3: Harm	C-LD	4. Adenosine should not be administered for hemodynamically unstable, irregularly irregular, or polymorphic wide-complex tachycardias.

- Adenosine
  - May be administered for treatment or diagnosis for regular monomorphic WCT
  - Should not be use for irregular/polymorphic WCT
- Amiodarone, procainamide, or sotalol
  - May be used to treat WCT of unknown etiology
- Verapamil
  - Avoid if etiology of WCT is unknown

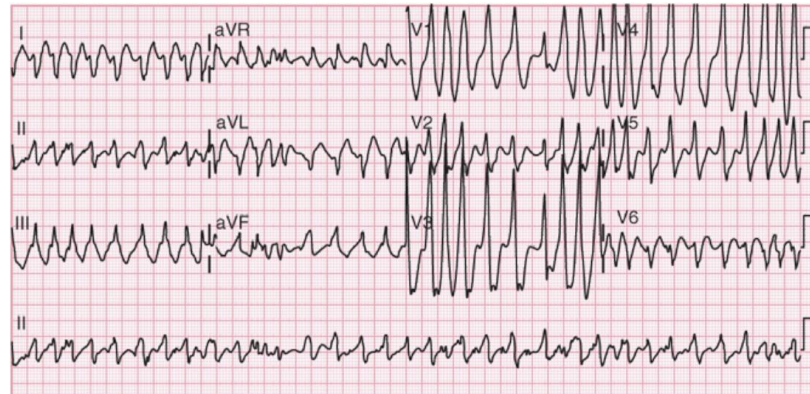
# Case #6

Patient was hemodynamically stable, so IV sotalol was administered, revealing typical atrial flutter. He was subsequently treated with external cardioversion.



# Case #7

A 43 year old man with Wolff-Parkinson-White syndrome was admitted to the surgical ICU after a motor vehicle crash with concussion but no evidence of skull fracture or intracranial hemorrhage. He developed abrupt onset tachycardia 200 bpm. He remained hemodynamically stable.

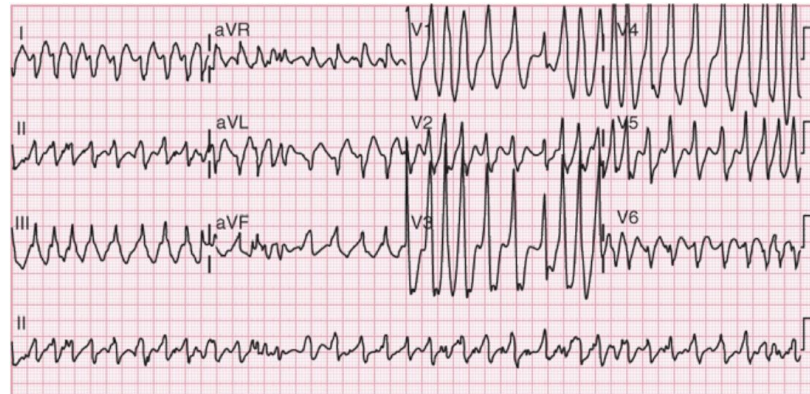


Which of the following would be the most appropriate next step in management?

- A) Intravenous metoprolol
- B) Intravenous verapamil
- C) Intravenous procainamide
- D) Intravenous digoxin
- E) Intravenous amiodarone

# Case #7

A 43 year old man with Wolff-Parkinson-White syndrome was admitted to the surgical ICU after a motor vehicle crash with concussion but no evidence of skull fracture or intracranial hemorrhage. He developed abrupt onset tachycardia 200 bpm. He remained hemodynamically stable.

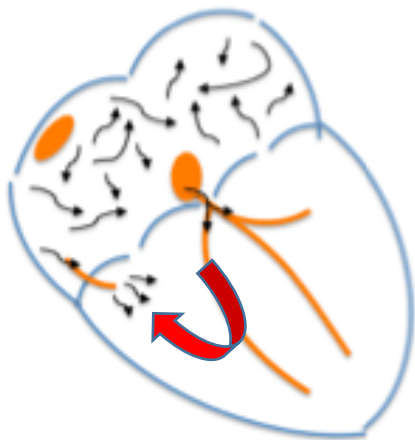


Which of the following would be the most appropriate next step in management?

- A) Intravenous metoprolol
- B) Intravenous verapamil
- C) Intravenous procainamide
- D) Intravenous digoxin
- E) Intravenous amiodarone

# Atrial fibrillation with Wolff Parkinson White Syndrome

- Avoid AV Nodal Blockers
  - Beta blockers
  - Calcium blockers
  - Digoxin
  - Adenosine
  - Amiodarone
- Treatment Options
  - Procainamide
  - Ibutilide
  - Electrical cardioversion



# Overview

- Bradycardias
  - Sinus arrest
  - AV Block
- Tachycardias
  - Ventricular Tachycardia
  - Unspecified Wide Complex Tachycardia
- **Cardiac Arrest**
  - Shockable rhythms
    - VF
    - Pulseless VT
  - Non-shockable rhythms
    - Asystole
    - Pulseless electrical activity (PEA)

# Case #8

A 70 year old woman with history of CAD and remote CABG was admitted to the hospital with acute decompensated heart failure and newly noted reduced LVEF 40% and global hypokinesis. There was no sign of acute coronary syndrome based upon EKG and laboratory evaluation. She was intubated for acute respiratory distress, started on dobutamine for cardiogenic shock, and admitted to the ICU. In the ICU, she developed pulseless ventricular tachycardia. CPR was started, and external shock was delivered, but failed to maintain sinus rhythm for more than few seconds. Epinephrine, additional shocks, and CPR were continued, but the patient remained in pulseless ventricular tachycardia.

What is the best next step in management?

- A) Intravenous amiodarone
- B) Intravenous calcium
- C) Sodium bicarbonate
- D) Intravenous magnesium
- E) Intravenous metoprolol

# Case #8

A 70 year old woman with history of CAD and remote CABG was admitted to the hospital with acute decompensated heart failure and newly noted reduced LVEF 40% and global hypokinesis. There was no sign of acute coronary syndrome based upon EKG and laboratory evaluation. She was intubated for acute respiratory distress, started on dobutamine for cardiogenic shock, and admitted to the ICU. In the ICU, she developed pulseless ventricular tachycardia. CPR was started, and external shock was delivered, but failed to maintain sinus rhythm for more than few seconds. Epinephrine, additional shocks, and CPR were continued, but the patient remained in pulseless ventricular tachycardia.

What is the best next step in management?

- A) Intravenous amiodarone
- B) Intravenous calcium
- C) Sodium bicarbonate
- D) Intravenous magnesium
- E) Intravenous metoprolol

# Part 3: Adult Basic and Advanced Life Support

## 2020 American Heart Association Guidelines for Cardiopulmonary Resuscitation and Emergency Cardiovascular Care

### Nonvasopressor Medications During Cardiac Arrest

Recommendations for Nonvasopressor Medications		
COR	LOE	Recommendations
2b	B-R	1. Amiodarone or lidocaine may be considered for VF/pVT that is unresponsive to defibrillation.
2b	C-LD	2. For patients with OHCA, use of steroids during CPR is of uncertain benefit.
3: No Benefit	B-NR	3. Routine administration of calcium for treatment of cardiac arrest is not recommended.
3: No Benefit	B-R	4. Routine use of sodium bicarbonate is not recommended for patients in cardiac arrest.
3: No Benefit	B-R	5. The routine use of magnesium for cardiac arrest is not recommended.

- Amiodarone or lidocaine may be considered for VF/pulseless VT

# Cardiac Arrest – Vasopressors

## Vasopressor Medications During Cardiac Arrest

Recommendations for Vasopressor Management in Cardiac Arrest		
COR	LOE	Recommendations
1	B-R	1. We recommend that epinephrine be administered for patients in cardiac arrest.
2a	B-R	2. Based on the protocols used in clinical trials, it is reasonable to administer epinephrine 1 mg every 3 to 5 min for cardiac arrest.
2a	C-LD	3. With respect to timing, for cardiac arrest with a nonshockable rhythm, it is reasonable to administer epinephrine as soon as feasible.
2b	C-LD	4. With respect to timing, for cardiac arrest with a shockable rhythm, it may be reasonable to administer epinephrine after initial defibrillation attempts have failed.
2b	C-LD	5. Vasopressin alone or vasopressin in combination with epinephrine may be considered in cardiac arrest but offers no advantage as a substitute for epinephrine in cardiac arrest.
3: No Benefit	B-R	6. High-dose epinephrine is not recommended for routine use in cardiac arrest.

- Epinephrine
  - Indicated for all cardiac arrest types
- Vasopressin
  - May be considered in combination with epinephrine

# Cardiac Arrest Resuscitation

- Insufficient evidence to support or refute use
  - Atropine
  - Corticosteroids
- Not recommended for routine use:
  - Calcium
  - Sodium bicarbonate
  - fibrinolytics

# Cardiac Arrest – Reversible Etiologies

## 5 “H”s

- Hypovolemia
- Hypoxia
- Hydrogen ions (Acidosis)
- Hypo-/Hyperkalemia
- Hypothermia

## 5 “T”s

- Tension Pneumothorax
- Tamponade
- Toxins
- Thrombosis (Pulmonary)
- Thrombosis (Coronary)

# Overview

- Bradycardias
  - Sinus arrest
  - AV Block
- Tachycardias
  - Ventricular Tachycardia
  - Unspecified Wide Complex Tachycardia
- Cardiac Arrest
  - Shockable rhythms
    - VF
    - Pulseless VT
  - Non-shockable rhythms
    - Asystole
    - Pulseless electrical activity (PEA)

# Summary Take Home Points - Bradycardia

- There is no specific heart rate or length of pause that warrants urgent pacing.
- Indication for intervention is based upon symptoms and/or instability.
- Interventions: Medications or pacing

# Summary Take Home Points - Tachycardia

- Wide complex tachycardia → Most often VT
- Unstable tachyarrhythmia → Cardiovert
- Stable VT → Procainamide; amiodarone; lidocaine; sotalol; beta blocker
- Torsades de Pointes → Mg and isoproterenol
- WPW → Avoid AV nodal blocking agents

# Summary Take Home Points – Cardiac Arrest

- CPR
- Epinephrine
- VF/pulseless VT → Electrical cardioversion +/- amiodarone or lidocaine
- Look for reversible causes (5 “H”s and 5 “T”s)

# Further Resources

## **Part 8: Advanced Life Support**

**2010 International Consensus on Cardiopulmonary Resuscitation and  
Emergency Cardiovascular Care Science With  
Treatment Recommendations**

Morrison. *Circulation*. 2010; 122(suppl 2): S345  
Focus on pages S351-S354

### **AHA FOCUSED UPDATE**

---

**2019 American Heart Association Focused Update on  
Advanced Cardiovascular Life Support: Use of Advanced  
Airways, Vasopressors, and Extracorporeal Cardiopulmonary  
Resuscitation During Cardiac Arrest**

An Update to the American Heart Association Guidelines for Cardiopulmonary  
Resuscitation and Emergency Cardiovascular Care

Panchal. *Circulation*. 2019; 140: e881  
Focus on pages e885-e888

## **Part 3: Adult Basic and Advanced Life Support**

**2020 American Heart Association Guidelines for Cardiopulmonary  
Resuscitation and Emergency Cardiovascular Care**

Panchal. *Circulation*. 2020;142 (suppl 2): S366

Review

**Initial evaluation and management of wide-complex tachycardia: A  
simplified and practical approach**

Littmann. *Am J Emerg Med*. 2019; 37: 1340

**The Society of Thoracic Surgeons Expert  
Consensus for the Resuscitation of Patients  
Who Arrest After Cardiac Surgery**



Dunning. *Ann Thorac Surg*. 2017; 103: 1005  
Focus on pages 1007-1014

The Society of Thoracic Surgeons Task Force on Resuscitation After Cardiac Surgery\*

BRIGHAM HEALTH



BRIGHAM AND  
WOMEN'S HOSPITAL

# Thank You! Questions?

**Thomas M. Tadros, MD, MPH**

*Cardiac Electrophysiologist*

*Brigham and Women's Hospital*

*Instructor*

*Harvard Medical School*

Email: [ttadros@partners.org](mailto:ttadros@partners.org)



HARVARD MEDICAL SCHOOL  
TEACHING HOSPITAL

MAGNET  
RECOGNIZED

